

# *IES CASE COMPETITION*

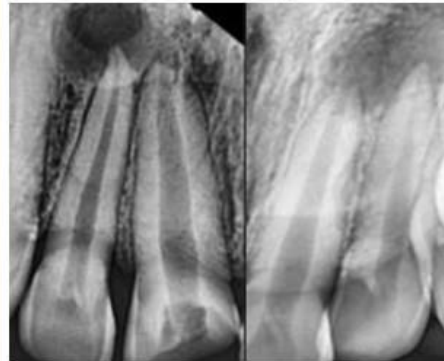
*ONLINE MOST POPULAR AWARDS*

*FIRST PRIZE*

*Dr DAKSHITHA JOY SINHA*

**IES Endo Case Competition 2023**

**Dr Dakshita Joy Sinha**



Non-invasive approach in treatment of large  
periradicular cyst like lesion: An alternative to  
surgery

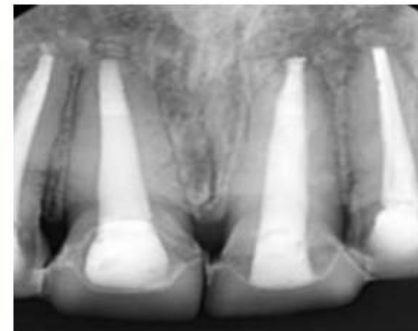


**INDIAN  
ENDODONTIC  
SOCIETY**



**IES Endo Case Competition 2023**

**Dr Dakshita Joy Sinha**



Non-invasive approach in treatment of large  
periradicular cyst like lesion: An alternative to  
surgery



**INDIAN  
ENDODONTIC  
SOCIETY**



# *IES CASE COMPETITION*

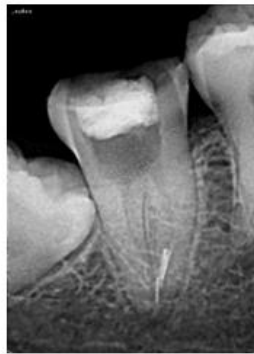*ONLINE MOST POPULAR AWARDS*

*SECOND PRIZE*

*Dr HARSH AMLANI*

**IES Endo Case Competition 2023**

**DR HARSH AMLANI**



Retrieval of 4 separated (2 non -visible)  
instruments from the Apical third of lower  
second molar

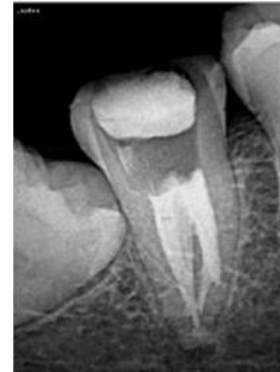

**INDIAN  
ENDODONTIC  
SOCIETY**



**IES Endo Case Competition 2023**

**DR HARSH AMLANI**



Retrieval of 4 separated (2 non -visible)  
instruments from the Apical third of lower  
second molar



**INDIAN  
ENDODONTIC  
SOCIETY**





# *IES CASE COMPETITION*

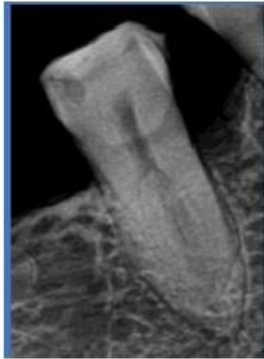*ONLINE MOST POPULAR AWARDS*

*THIRD PRIZE*

*Dr KSHITIJ SAMEER JOSHI*

**IES Endo Case Competition 2023**

**DR.KSHITIJ SAMEER JOSHI**



Endodontic Treatment Of Mandibular Second  
Premolar With Sert & Bayirili's 4-1 Canal  
Configuration

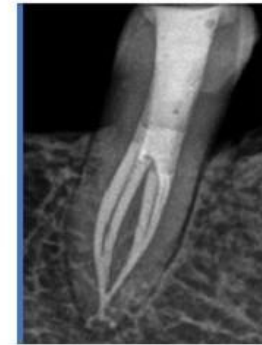

**INDIAN  
ENDODONTIC  
SOCIETY**



**IES Endo Case Competition 2023**

**DR.KSHITIJ SAMEER JOSHI**



Endodontic Treatment Of Mandibular Second  
Premolar With Sert & Bayirili's 4-1 Canal  
Configuration



**INDIAN  
ENDODONTIC  
SOCIETY**



# IES CASE COMPETITION

## EXPERT RECOGNITION AWARDS

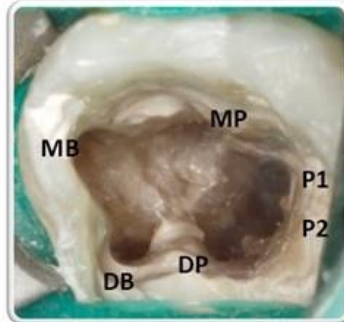
### FIRST PRIZE

*Dr USHAINA E. FANIBUNDA*

#### IES Endo Case Competition 2023

DR USHAINA E FANIBUNDA

ACCESS CAVITY SHOWING 6 CANALS

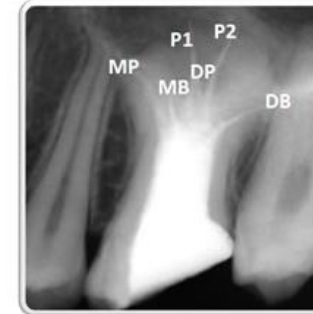

Multiple canals in a hypertaurodont maxillary molar: an unusual case report

#### IES Endo Case Competition 2023

DR USHAINA E FANIBUNDA

POST-OBTURATION X-RAY



Multiple canals in a hypertaurodont maxillary molar: an unusual case report



# IES CASE COMPETITION

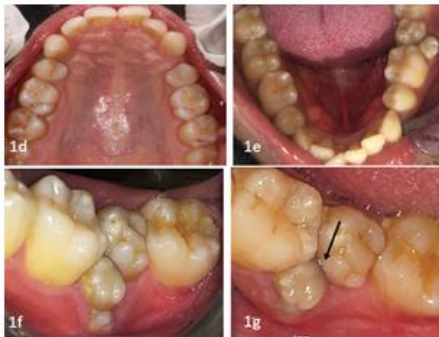## EXPERT RECOGNITION AWARDS

### SECOND PRIZE

Dr ANKIT ARORA

#### IES Endo Case Competition 2023

DR ANKIT ARORA

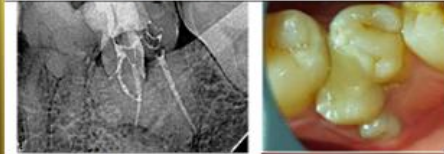

Endodontic treatment of a "Germinated Composite Odontome": Restoring belief in endodontics

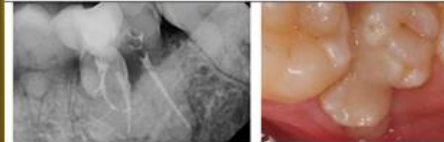
#### IES Endo Case Competition 2023

DR ANKIT ARORA

16 month follow up. Intact restoration with healthy periodontium.



2 years follow up. Intact restoration with healthy periodontium



Endodontic treatment of a "Germinated Composite Odontome": Restoring belief in endodontics

# IES CASE COMPETITION

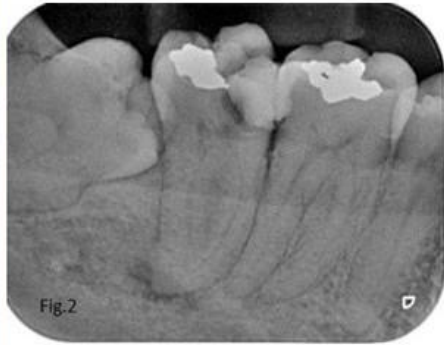*EXPERT RECOGNITION AWARDS*

*SECOND PRIZE*

*Dr RAGHAVENDRA P*

**IES Endo Case Competition 2023**

**Dr RAGHAVENDRA P**



Non-Surgical Endodontic Management of a Severely Curved Root Canals in Mandibular Second Molar Using Tactile-Controlled Activation Instrumentation

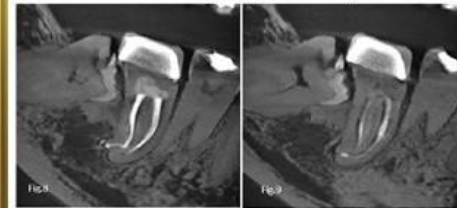


**INDIAN  
ENDODONTIC  
SOCIETY**



**IES Endo Case Competition 2023**

**Dr RAGHAVENDRA P**



Non-Surgical Endodontic Management of a Severely Curved Root Canals in Mandibular Second Molar Using Tactile-Controlled Activation Instrumentation



**INDIAN  
ENDODONTIC  
SOCIETY**





# *IES CASE COMPETITION*

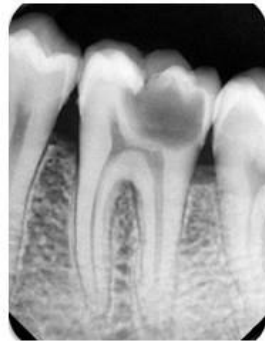## *EXPERT RECOGNITION AWARDS*

### *THIRD PRIZE*

*Dr RAMESH RAJENDRAN*

**IES Endo Case Competition 2023**

**DR RAMESH RAJENDRAN**



Pioneering Precision & Conservation in Endovital  
Therapy using PEIGS

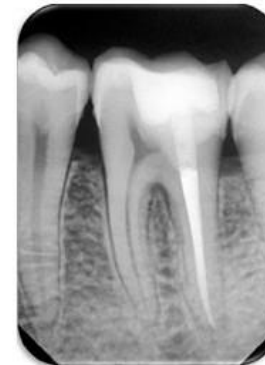


INDIAN  
ENDODONTIC  
SOCIETY



**IES Endo Case Competition 2023**

**DR RAMESH RAJENDRAN**



Pioneering Precision & Conservation in Endovital  
Therapy using PEIGS



INDIAN  
ENDODONTIC  
SOCIETY



# *IES CASE COMPETITION*

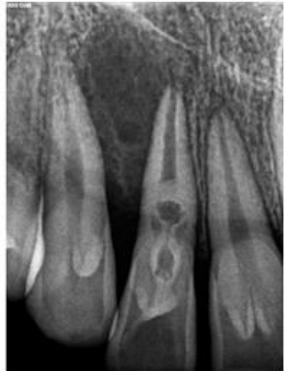## *EXPERT RECOGNITION AWARDS*

### *THIRD PRIZE*

*Dr ROHEET KHATAVKAR*

#### **IES Endo Case Competition 2023**

**DR ROHEET KHATAVKAR**



NSRCT of rare case of Bilateral Double  
Dens Invaginatus

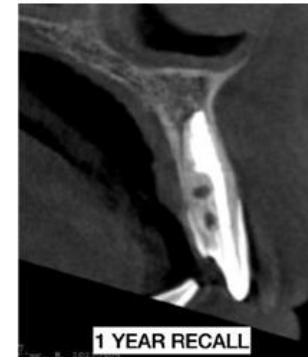

**INDIAN  
ENDODONTIC  
SOCIETY**



#### **IES Endo Case Competition 2023**

**DR ROHEET KHATAVKAR**



NSRCT of rare case of Bilateral Double  
Dens Invaginatus



**INDIAN  
ENDODONTIC  
SOCIETY**





# *IES CASE COMPETITION*

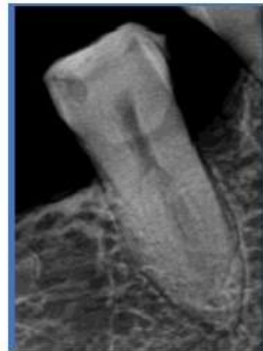## *EXPERT RECOGNITION AWARDS*

### *THIRD PRIZE*

*Dr KSHITIJ SAMEER JOSHI*

#### **IES Endo Case Competition 2023**

**DR.KSHITIJ SAMEER JOSHI**



Endodontic Treatment Of Mandibular Second  
Premolar With Sert & Bayirili's 4-1 Canal  
Configuration

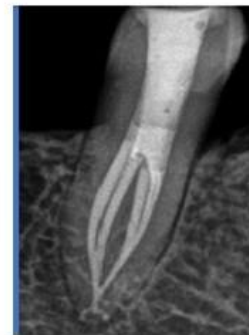

**INDIAN  
ENDODONTIC  
SOCIETY**



#### **IES Endo Case Competition 2023**

**DR.KSHITIJ SAMEER JOSHI**



Endodontic Treatment Of Mandibular Second  
Premolar With Sert & Bayirili's 4-1 Canal  
Configuration



**INDIAN  
ENDODONTIC  
SOCIETY**



# *IES CASE COMPETITION*

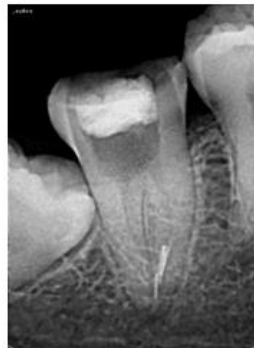## *EXPERT RECOGNITION AWARDS*

### *FOURTH PRIZE*

*Dr HARSH AMLANI*

#### **IES Endo Case Competition 2023**

**DR HARSH AMLANI**



Retrieval of 4 separated (2 non -visible)  
instruments from the Apical third of lower  
second molar

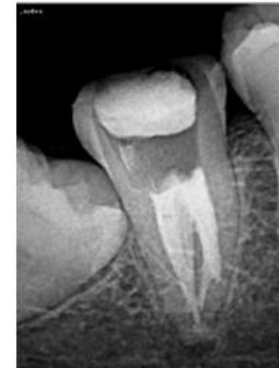

**INDIAN  
ENDODONTIC  
SOCIETY**



#### **IES Endo Case Competition 2023**

**DR HARSH AMLANI**



Retrieval of 4 separated (2 non -visible)  
instruments from the Apical third of lower  
second molar



**INDIAN  
ENDODONTIC  
SOCIETY**





# *IES CASE COMPETITION*

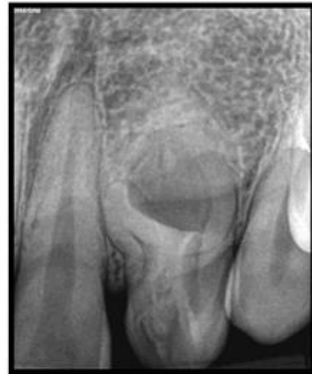## *EXPERT RECOGNITION AWARDS*

### *FOURTH PRIZE*

*Dr ABHISHEK MYSORE ANIL*

#### **IES Endo Case Competition 2023**

**DR ABHISHEK MYSORE ANIL**



Endodontic treatment of a dens invaginatus in  
maxillary lateral incisor : A case report

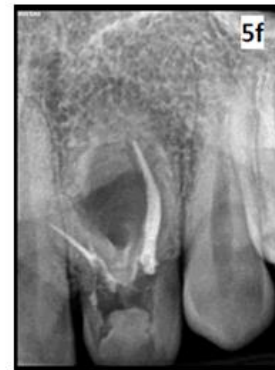

**INDIAN  
ENDODONTIC  
SOCIETY**



#### **IES Endo Case Competition 2023**

**DR ABHISHEK MYSORE ANIL**



Endodontic treatment of a dens invaginatus in  
maxillary lateral incisor : A case report



**INDIAN  
ENDODONTIC  
SOCIETY**



# IES CASE COMPETITION

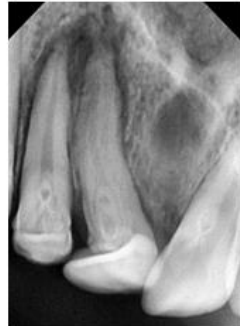## EXPERT RECOGNITION AWARDS

### FOURTH PRIZE

*Dr SOURABH BARBHAI*

#### IES Endo Case Competition 2023

DR SOURABH BARBHAI



NON SURGICAL ENDODONTIC MANAGEMENT OF  
SEVERELY DILACERATED MAXILLARY CENTRAL INCISOR  
WITH TYPE III DENS INVAGINATUS USING NOVEL  
BIOACTIVE GLASS BASED SEALER -A CASE REPORT

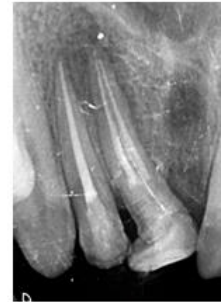

INDIAN  
ENDODONTIC  
SOCIETY



#### IES Endo Case Competition 2023

DR SOURABH BARBHAI



12 months follow up

NON SURGICAL ENDODONTIC MANAGEMENT OF  
SEVERELY DILACERATED MAXILLARY CENTRAL INCISOR  
WITH TYPE III DENS INVAGINATUS USING NOVEL  
BIOACTIVE GLASS BASED SEALER -A CASE REPORT



INDIAN  
ENDODONTIC  
SOCIETY





# *IES CASE COMPETITION*

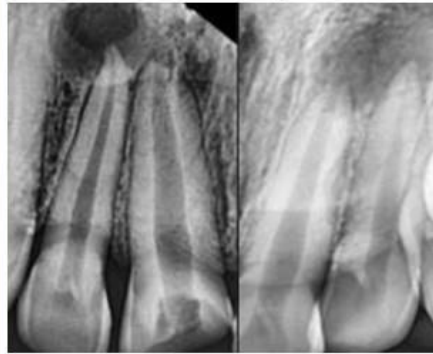
## *EXPERT RECOGNITION AWARDS*

### *FOURTH PRIZE*

*Dr DAKSHITHA JOY SINHA*

**IES Endo Case Competition 2023**

**Dr Dakshita Joy Sinha**



Non-invasive approach in treatment of large periradicular cyst like lesion: An alternative to surgery

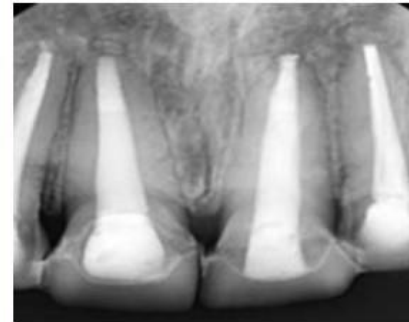


INDIAN  
ENDODONTIC  
SOCIETY



**IES Endo Case Competition 2023**

**Dr Dakshita Joy Sinha**



Non-invasive approach in treatment of large periradicular cyst like lesion: An alternative to surgery



INDIAN  
ENDODONTIC  
SOCIETY

